

Case Report

Unraveling the quivering dance: Trichomoniasis

Archana Rajan¹, Nishtha Kapil² Departments of ¹Medicine, ²Laboratory Medicine, All India Institute of Medical Sciences (AIIMS), Delhi, India.

ABSTRACT

This case report delves into an atypical presentation of trichomoniasis in a previously healthy 56-year-old female. Presenting with burning micturition and pruritus, the patient's urine microscopy revealed characteristic twisting motility of *Trichomonas vaginalis*, confirming the diagnosis. Treatment with metronidazole resulted in prompt symptomatic improvement. This case underscores the importance of recognizing diverse presentations of Trichomoniasis for accurate diagnosis and timely intervention.

Keywords: Trichomoniasis, Urinary tract infection, Sexually transmitted diseases

INTRODUCTION

Trichomoniasis, caused by *Trichomonas vaginalis*, commonly manifests as urogenital infections. This case delves into an unusual presentation of the infection, emphasizing the need for clinicians to consider diverse clinical scenarios.

CASE REPORT

A 56-year-old female with no prior comorbidity presented with complaints of burning micturition, pruritus and increased frequency of urine for the past 1 week. On further probing, she revealed occasional grayish-white discharge which she considered insignificant. On examination, she was vitally stable and systemic examination was unremarkable. Her laboratory examination revealed a total leucocyte count-15,240/ μ L, with 86.1% neutrophils (reference range, 48–76), 12.8% lymphocytes (reference range, 18–41), 2.1% monocytes (reference range, 4–11), the hemoglobin level was 13.6 g/dL, and the platelet count 338,000 per microliter. The erythrocyte sedimentation rate was 50 mm/h (reference range, 0–20), and the C-reactive protein level was 38 mg/L (normal <10 mg/L), kidney function test and blood sugar level were within normal limits. With suspicion of urinary tract infection, we did a urine routine microscopy revealed characteristic twisting motility or quivering motility of which *T. vaginalis* [Figures 1 and 2]. Thus, a diagnosis of trichomoniasis was made. She was treated with 7-day course of 500 mg metronidazole twice daily following which she improved symptomatically and symptoms did not recur.^[1]

DISCUSSION

T. vaginalis is pear-shaped or oval in appearance, with a size ranging from 10 μ m to 20 μ m in length, has four flagella, which are whip-like structures that extend from the front of the organism, along with an undulating membrane, which is a thin, wavy membrane extending along the organism's length. The parasite contains a single, centrally located nucleus, which is often visible in the body of the organism and cytoplasm of *T. vaginalis* appears granular and may contain ingested bacteria, erythrocytes, or other debris.^[2]

Trichomoniasis, caused by the protozoan parasite *T. vaginalis*, commonly manifests as a urogenital infection. In this case, the patient's atypical presentation with burning micturition, pruritus, and increased urine frequency prompted a thorough diagnostic investigation. The identification of characteristic twisting motility of *T. vaginalis* in urine microscopy was pivotal in confirming the diagnosis.

The patient's lack of prior comorbidities and the absence of typical risk factors for Trichomoniasis make this case noteworthy. The atypical presentation underscores the importance of maintaining a high index of suspicion for parasitic infections even in patients without conventional risk factors. Moreover, the patient's asymptomatic grayish-white discharge, initially considered insignificant, serves as a reminder that subtle symptoms may be indicative of underlying infections and warrant careful exploration during clinical assessments.

*Corresponding author: Archana Rajan, Department of Medicine, All India Institute of Medical Sciences (AIIMS), Delhi, India. archanarajan29@gmail.com

Received: 21 November 2023 Accepted: 28 February 2024 Epub Ahead of Print: 09 May 2024 Published: XXXXX DOI: 10.25259/IJMS_233_2023

This is an open-access article distributed under the terms of the Creative Commons Attribution-Non Commercial-Share Alike 4.0 License, which allows others to remix, transform, and build upon the work non-commercially, as long as the author is credited and the new creations are licensed under the identical terms. ©2024 Published by Scientific Scholar on behalf of Indian Journal of Medical Sciences

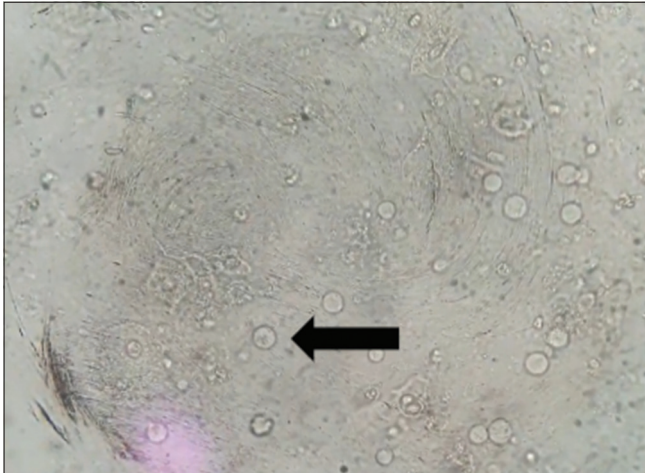


Figure 1: Urine microscopic examination showing field full of *Trichomonas vaginalis* (black arrowhead).

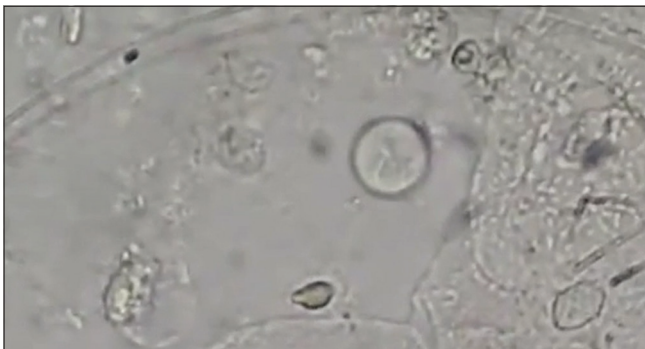

Figure 2: Urine microscopic examination of same patient- *Trichomonas vaginalis*-internal structure is also visible.

The laboratory findings revealed an elevated total leucocyte count with a predominance of neutrophils, indicating an inflammatory response to the infection. The inflammatory markers, including an elevated erythrocyte sedimentation rate and C-reactive protein level, further supported the diagnosis. While these laboratory parameters are nonspecific, they contribute to the overall clinical picture, emphasizing the need for a comprehensive diagnostic approach.

The prompt resolution of symptoms following a 7-day course of metronidazole highlights the efficacy of targeted treatment for trichomoniasis. The patient's favorable response aligns with established guidelines for managing this parasitic infection, emphasizing the importance of accurate identification for appropriate therapeutic interventions.

CONCLUSION

This case illuminates an uncommon presentation of trichomoniasis, emphasizing the necessity of a comprehensive diagnostic strategy. Recognition of the characteristic motility in urine microscopy enabled precise diagnosis and effective treatment. Clinicians should remain vigilant for diverse presentations of trichomoniasis to enhance timely intervention.

Acknowledgment

To co-author for data collection and concept.

Ethical approval

Institutional Review Board approval is not required.

Declaration of patient consent

Patient's consent not required as patients identity is not disclosed or compromised.

Financial support and sponsorship

Nil.

Conflicts of interest

There are no conflicts of interest.

Use of artificial intelligence (AI)-assisted technology for manuscript preparation

The authors confirm that there was no use of artificial intelligence (AI)-assisted technology for assisting in the writing or editing of the manuscript and no images were manipulated using AI.

REFERENCES

1. Kissinger PJ, Gaydos CA, Seña AC, McClelland RS, Soper D, Secor WE, *et al.* Diagnosis and management of trichomonas vaginalis: Summary of evidence reviewed for the 2021 centers for disease control and prevention sexually transmitted infections treatment guidelines. *Clin Infect Dis* 2022;74(Suppl_2):S152-61.
2. Schumann JA, Plasner S. Trichomoniasis. In: StatPearls. Treasure Island, FL: StatPearls Publishing; 2023. Available from: <http://www.ncbi.nlm.nih.gov/books/NBK534826> [Last accessed on 2023 Aug 09].

How to cite this article: Rajan A, Kapil N. Unraveling the quivering dance: Trichomoniasis. *Indian J Med Sci.* doi: 10.25259/IJMS_233_2023