

Viewpoint

Integration of hyperthermic intraperitoneal chemotherapy with cytoreductive surgery for ovarian cancer in Iraq: Navigating challenges in a resource-limited setting

Aqeel Shakir Mahmood¹, Ahmed A. Shakir², Samer Sabri²

¹Department of Surgery, University of Baghdad, College of Medicine, ²Department of Surgery, Baghdad Teaching Hospital, Baghdad, Iraq.

ABSTRACT

In Iraq, the application of hyperthermic intraperitoneal chemotherapy combined with cytoreductive surgery is a novel therapeutic strategy for ovarian cancer with peritoneal carcinomatosis. This study at the Arby Private Hospital represents the pioneering use of this modality in a resource-limited setting. It evaluates procedural effectiveness, elucidates the systemic challenges within the healthcare framework, and identifies the imperatives for medical training enhancement. The findings illuminate the clinical viability and outline necessary strategies for broader integration of advanced therapies into the Iraqi health-care paradigm, emphasizing a pressing need for policy and infrastructural reforms to elevate oncologic care.

Keywords: Hyperthermic intraperitoneal chemotherapy, Ovarian cancer, Cytoreductive surgery, Iraq

INTRODUCTION

Ovarian cancer with peritoneal involvement presents a formidable challenge in oncology. The adaptation of hyperthermic intraperitoneal chemotherapy (HIPEC) with cytoreductive surgery (CRS) as a treatment modality in Iraq is a testament to the progressive strides in the nation's oncologic landscape.^[1,2] This sophisticated intervention reflects an alignment with the global shift toward more aggressive management of ovarian cancer, but it also brings to light the infrastructural, educational, and resource-based constraints faced by Iraqi health-care institutions.^[3,4] This paper focuses on the initial experiences, challenges, and the potential framework for the future of HIPEC with CRS in the Iraqi context.

IRAQ EXPERIENCE

Our focused study at Arby Private Hospital targeted ovarian cancer patients with peritoneal carcinomatosis, an advanced stage of the disease often associated with a poor prognosis. Between January 13, 2019, and October 26, 2019, we introduced the combined use of CRS and HIPEC for the first time in Iraq. Out of 34 patients in our cohort, two presented with ovarian cancer [Figure 1], highlighting a concentrated perspective on the disease's management through HIPEC

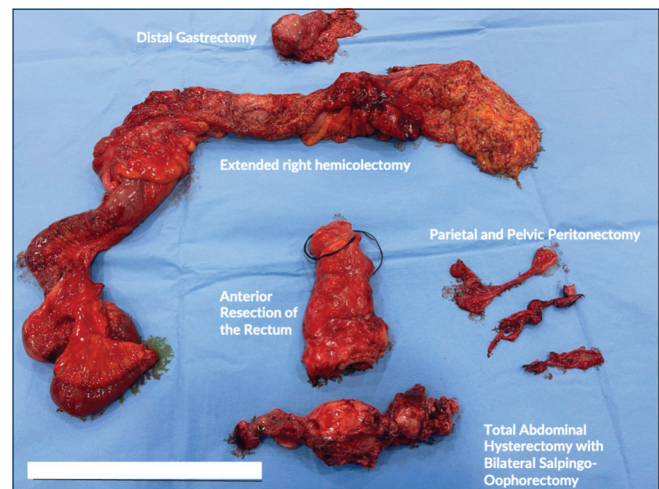


Figure 1: Surgical specimens resulting from cytoreductive surgery (CRS), including distal gastrectomy, right hemicolectomy, rectal resection, peritonectomy, and a total abdominal hysterectomy with bilateral salpingo-oophorectomy. These procedures are part of the CRS, which is often followed by hyperthermic intraperitoneal chemotherapy for the management of peritoneal carcinomatosis.

with CRS. These patients were meticulously selected using a variety of diagnostic tools, including contrast-enhanced computed tomography, magnetic resonance imaging,

*Corresponding author: Aqeel Shakir Mahmood, Department of Surgery, University of Baghdad, College of Medicine, Baghdad, Iraq. aqeel.shakir.mahmood@gmail.com

Received: 08 January 2024 Accepted: 19 June 2024 Epub ahead of print: 29 August 2024 Published: 21 October 2024 DOI: 10.25259/IJMS_6_2024

This is an open-access article distributed under the terms of the Creative Commons Attribution-Non Commercial-Share Alike 4.0 License, which allows others to remix, transform, and build upon the work non-commercially, as long as the author is credited and the new creations are licensed under the identical terms. ©2024 Published by Scientific Scholar on behalf of Indian Journal of Medical Sciences

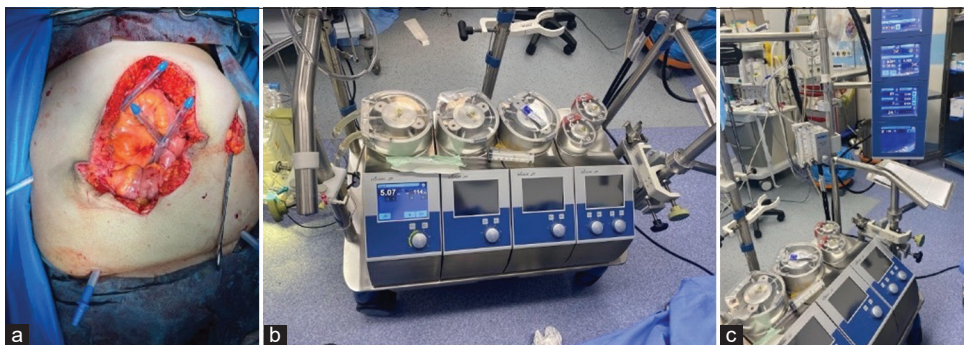


Figure 2: (a) An intraoperative view during a hyperthermic intraperitoneal chemotherapy (HIPEC) procedure, showcasing the abdominal cavity post-cytoreductive surgery. Here, inflow and outflow catheters are placed, indicating the preparation for the HIPEC phase, where heated chemotherapeutic agents will be circulated to target microscopic residual cancer cells within the peritoneal cavity. (b and c) The machinery used in HIPEC. They display the perfusion system which controls the temperature and flow of the chemotherapeutic agent within the peritoneal cavity, a crucial component in the HIPEC procedure.

positron emission tomography, serum tumor markers, and diagnostic laparoscopy. The center's attributes, such as experience, certification, and involvement in register studies, were also key factors in patient selection. This selection underscores the stringent criteria employed—considering overall health, cancer staging, and the absence of extensive metastasis. Over the follow-up phase, which lasted until October 26, 2023, these patients were observed for a duration of 4 years, providing valuable long-term data. The diversity in the primary sites of cancer in the broader cohort provided comparative insights, but the ovarian cancer subset allowed for an in-depth analysis of treatment responses and surgical challenges particular to this group.^[3]

CURRENT CHALLENGES

The implementation of HIPEC following CRS in Iraq, particularly in advanced centers such as the Arby Private Hospital, marks a significant step in cancer treatment but is beset with several challenges. The limited availability of this advanced treatment, primarily restricted to specialized centers, underscores a gap in broader accessibility across the country. Variability in the level of expertise among Iraqi oncologists and surgeons further highlights the need for enhanced training and knowledge-sharing initiatives to ensure the effective administration of HIPEC [Figure 2].

Compounding these challenges is the developing state of necessary infrastructure for HIPEC, which includes acquiring specialized equipment and facilities. This issue is particularly acute in the governmental health-care sector, where HIPEC's unavailability precludes public access to this advanced treatment, thus creating a significant barrier in democratizing cancer care. In the private sector, while HIPEC is accessible, it is often prohibitively expensive for many patients. In addition, the scarcity of specialized expertise in

effectively managing HIPEC treatments further complicates its functionality and success in Iraq.

Implementing HIPEC with CRS in Iraq involved overcoming significant challenges, particularly in securing equipment and setting up initial infrastructure. Negotiating with companies to provide the necessary equipment and setup proved difficult, given the limited availability and high costs. In addition, the patient education was a major hurdle, as HIPEC is a novel and uncommon treatment in Iraq. These challenges were addressed through strategic partnerships, securing donations, and comprehensive patient counseling to ensure understanding and consent.

CONCLUSION

The introduction of HIPEC with CRS for ovarian cancer at the Arby Private Hospital marks a critical milestone in Iraq's oncologic services. However, the promise of this advanced treatment is tempered by challenges that impede its widespread adoption. To realize the full potential of HIPEC with CRS, concerted efforts must be made to improve access, enhance professional training, and invest in the necessary infrastructure. With strategic policy support and resource allocation, HIPEC can become an integral component of ovarian cancer care in Iraq, with the potential to significantly improve survival outcomes for women afflicted with this disease.

Ethical approval

Institutional Review Board approval is not required.

Declaration of patient consent

The authors certify that they have obtained all appropriate patient consent.

Financial support and sponsorship

Nil.

Conflicts of interest

There are no conflicts of interest.

Use of artificial intelligence (AI)-assisted technology for manuscript preparation

The authors confirm that there was no use of artificial intelligence (AI)-assisted technology for assisting in the writing or editing of the manuscript and no images were manipulated using AI.

REFERENCES

1. Ray MD, Dhall K. Hyperthermic intraperitoneal chemotherapy (HIPEC) in the management of peritoneal surface malignancies - an evidence-based review. *Curr Probl Cancer* 2021;45:100737.

2. Harper MM, Kim J, Pandalai PK. Current trends in cytoreductive surgery (CRS) and hyperthermic intraperitoneal chemotherapy (HIPEC) for peritoneal disease from appendiceal and colorectal malignancies. *J Clin Med* 2022;11:2840.
3. González Gil A, Cerezuela Fernández-de Palencia Á, Gómez Ruiz ÁJ, Gil Gómez E, López Hernández F, Nieto Ruiz A, *et al.* HIPEC in ovarian cancer is the future... and always will be? results from a Spanish multicentric survey. *Cancers (Basel)* 2023;15:3481.
4. Mahmood AS, Altameemi EA, Shakir AA, Sabri S, Ismail M. The challenges of breast conservative surgery in multifocal breast cancer: The first insights from Iraq experience. *Indian J Med Sci* 2023;75:185-6.

How to cite this article: Mahmood AS, Shakir AA, Sabri S. Integration of hyperthermic intraperitoneal chemotherapy with cytoreductive surgery for ovarian cancer in Iraq: Navigating challenges in a resource-limited setting. *Indian J Med Sci.* 2024;76:147-9. doi: 10.25259/IJMS_6_2024