

Case Report

Reactivation of cytomegalovirus infection in a post-COVID patient leading to cytomegalovirus pneumonia and colitis

Shikha Sachan¹, Ashok Kumar Singh¹, Aditya Nath Shukla¹¹Department of Critical Care, Regency Hospital, Kanpur, Uttar Pradesh, India.**ABSTRACT**

COVID-19 is a severe disease characterized by a multifactorial immunodeficient state in critically ill patients who have had no prior immunodeficiencies. Much of the mortality in COVID has been attributed to an unprecedented high number of secondary coinfections ranging from bacterial pneumonia to opportunistic infections such as invasive aspergillosis and mucormycosis. Case reports reporting reactivation of cytomegalovirus (CMV) infection are scanty. To the best of our knowledge, we describe one of the very few cases of a previously immunocompetent healthy individual who suffered from reactivation of CMV infection and involvement of invasive infection (CMV pneumonia and CMV colitis).

Keywords: COVID-19, Cytomegalovirus, Cytomegalovirus pneumonia, Cytomegalovirus colitis

INTRODUCTION

COVID-19 pandemic has been notorious for a very high mortality rate. Much of the mortality has been attributed to an unprecedented high number of secondary coinfections ranging from bacterial pneumonia to opportunistic infections such as invasive aspergillosis^[1] and mucormycosis.^[2] The high rate of secondary infections in previously immunocompetent patients affected with COVID pneumonia has given strength to the hypothesis that COVID-19 infection can lead to an acquired immunodeficiency which makes a patient vulnerable to a host of opportunistic infections. Previous immunocompromised status, COVID-associated lymphopenia,^[3] use of steroids^[4] and immunomodulatory therapy, prolonged mechanical ventilation, and nosocomial sepsis can all contribute to an exaggerated acquired immunodeficiency in a COVID patient.

Asymptomatic cytomegalovirus (CMV) infection evolving into a latent phase of controlled replication is very common in the adult population and is harmless. Reactivation of CMV, leading to tissue invasive disease and end-organ involvement, is known to occur in patients who are immunocompromised such as recipients of solid organ transplants, pregnant females, and H.I.V.^[5]

Medical literature is replete with COVID patients acquiring coinfection with opportunistic infections such as invasive aspergillosis and mucormycosis, but case reports reporting coinfection with invasive CMV infection are scanty.

We report a case of activation of CMV infection in a relatively young 52 years old, previously immunocompetent gentleman, leading to severe CMV pneumonitis and CMV colitis.

CASE REPORT

A 52-year-old gentleman, with no known previous comorbidities before his illness, was admitted to a dedicated COVID facility after he had symptoms of severe COVID pneumonia followed by positive nasopharyngeal RT-PCR and CORADS score 6/6 on CT scan thorax. On days 13th and 15th, he tested negative for two consecutive COVID RTPCRs. As he had a persistent high oxygen demand, he was referred immediately to our site for further post-COVID management. He had received a course of steroids, low-molecular-weight heparin, remdesivir, and broad-spectrum antibiotics. On arrival, he had significant breathing difficulty so he was put on non-invasive ventilation and further laboratory tests were done. Arterial blood gas showed PaO₂ of 55 mmHg on 80% FiO₂, total lymphocyte count (TLC) of 18,000 with low absolute lymphocyte count, elevated procalcitonin 4.8. X-ray chest showed the right lower zone opacities consistent with lobar pneumonia. This led us to suspect secondary bacterial pneumonia (likely nosocomial). Broad-spectrum empirical antibiotics (meropenem and polymyxin) were started.

On day 2nd, the patient was intubated and taken on mechanical ventilation, endotracheal aspirate was sent for microbiological culture and sensitivity. The patient responded to antibiotic

*Corresponding author: Shikha Sachan, Department of Critical Care, Regency Hospital, Kanpur, Uttar Pradesh, India. drshikhasachan11@gmail.com

Received: 20 January 2022 Accepted: 31 January 2022 Published: 11 May 2022 DOI 10.25259/IJMS_29_2022

This is an open-access article distributed under the terms of the Creative Commons Attribution-Non Commercial-Share Alike 4.0 License, which allows others to remix, transform, and build upon the work non-commercially, as long as the author is credited and the new creations are licensed under the identical terms. ©2022 Published by Scientific Scholar on behalf of Indian Journal of Medical Sciences

and supportive treatment, although still required ventilatory support. His subsequent microbiology report showed growth of pan drug-resistant *Pseudomonas* and *Escherichia coli*, sensitive to polymyxin B, but resistant to meropenem. Meropenem was stopped and ceftazidime-avibactam combination along with polymyxin B was instituted. The patient continued to show clinical improvement, with a gradual reduction in the right lower zone opacity on the X-ray chest, and some improvement in PaO₂/Fio₂ ratio.

On day 9th, bedside percutaneous tracheostomy was done which was uneventful. From day 13, the patient started to have intermittent febrile episodes, with a new appearance of bilateral chest opacities on X-ray. An HRCT thorax was done with showed the bilateral new appearance of diffuse ground-glass opacities, few borderline size mediastinal lymph nodes consistent with acute infection, superimposed on areas of architectural distortion, and traction bronchiectasis [Figure 1]. Serum procalcitonin was normal, TLC was 12,000 with persistent absolute lymphopenia.

We sent an endotracheal sample for bacterial culture and sensitivity, along with serum 1,3-beta-D-glucan for the possibility of *Pneumocystis jirovecii* and invasive fungal infection, and CMV serology (IgG and IgM titer) for diagnosis of active CMV pneumonia. Empirical treatment with intravenous cotrimoxazole for *Pneumocystis jirovecii* was started. However, his condition continued to be unstable, his ventilatory support was escalated, and he required mild vasopressor support with noradrenaline.

Subsequently, his serum 1,3-beta-D-glucan was negative, but CMV serology was positive (high titers of IgG and IgM indicative of possible CMV pneumonitis). We sent a sample for qualitative CMV DNA PCR as quantitative assay was unavailable. While the PCR test was awaited, the patient was started on valganciclovir tablets.

On day 16th, the patient started to show signs of gastrointestinal symptoms including intolerance to enteral feed, progressive abdominal distention, hemodynamic instability, decreased urine output, and increased serum creatinine. On day 18th, a non-contrast CT scan of the abdomen was done which revealed marked distention of cecum, ascending, and transverse colon, with intramural bowel gas within cecum, ascending, and transverse colon (pneumatosis intestinalis) [Figure 2]. Subsequently, CMV DNA PCR was positive for active CMV infection. We switched the patient to intravenous ganciclovir due to gastrointestinal intolerance.

The corroborative findings of new-onset atypical pneumonitis, severe colitis, positive radiological findings, raised CMV IgG and IgM titer, and positive qualitative CMV DNA PCR helped us establish a diagnosis of reactivated tissue invasive CMV infection with end-organ damage. We discussed with attendants the need for bronchoscopy alveolar lavage, lung tissue biopsy, sigmoidoscopy, and colon

biopsy. These tests were, however, not done due to rapidly deteriorating clinical parameters and the unwillingness of attendants toward future invasive tests.

On day 20, the patient succumbed to his illness, following a fatal cardiorespiratory arrest.

DISCUSSION

COVID-19 is a viral disease associated with unprecedented mortality and morbidity. Part of it can be attributed to dysregulated immune response^[6] and acquired

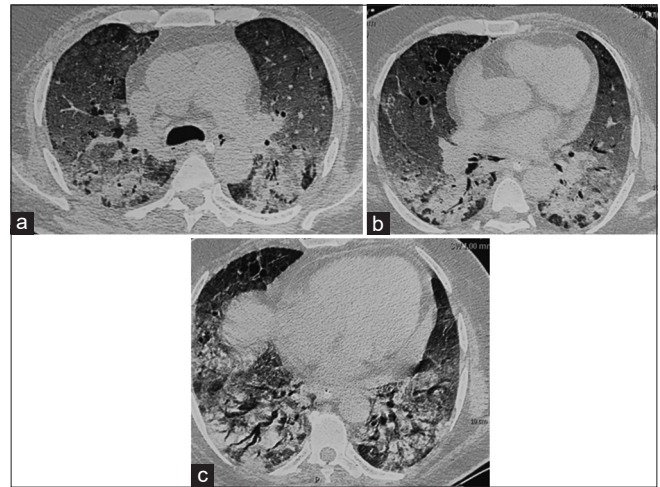


Figure 1: (a-c) A 52-year-old male, post-COVID pneumonia with new appearance of bilateral chest opacities on X-ray. An HRCT thorax was done with showed bilateral new appearance of diffuse ground-glass opacities, few borderline size mediastinal lymph nodes consistent with acute infection, superimposed on areas of architectural distortion, and traction bronchiectasis.

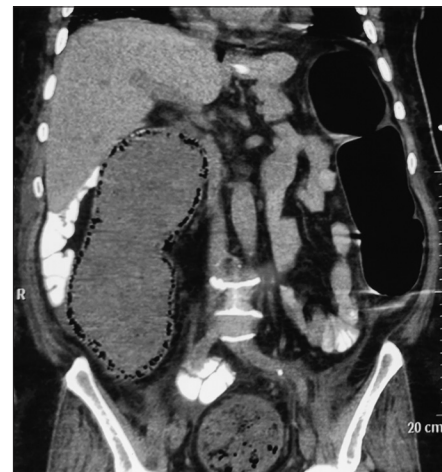


Figure 2: Non-contrast CT scan of abdomen revealed marked distention of cecum, ascending, and transverse colon, with intramural bowel gas within cecum, ascending, and transverse colon (pneumatosis intestinalis).

immunodeficiency, especially in critically ill patients. Absolute lymphopenia and depleted T cells are described as a hallmark of immunodeficiency in COVID patients. This can lead to a host of opportunistic infections. Medical literature is replete with COVID-19 and opportunistic infections such as invasive aspergillosis and mucormycosis. However, reports of invasive CMV infection are much less widely reported. Reporting of CMV and COVID-19 coinfection in India is even much scanty, even though we have had one of the highest mortalities during the pandemic. This can be attributed to resource limitation, late diagnosis, and the paucity of tests available for CMV detection. To the best of our knowledge, ours is one of the very few cases describing opportunistic and invasive CMV infection leading to end-organ damage of two systems, respiratory and gastrointestinal in a post-COVID patient.^[7,8]

CMV is a virus belonging to the Herpesviridae family. Asymptomatic infection is fairly common. The virus is known to never be completely eradicated from the body and undergoes controlled replication without harm to the human body. However, immunodeficient states can trigger reactivation of the virus, leading to tissue invasive disease and end-organ damage.

Our patient was a relatively young immunocompetent male adult, with no known comorbidities. However, his severe COVID pneumonia led to persistent absolute lymphopenia. He had also received a long course of corticosteroids and received antiviral (remdesivir). During the disease, he suffered from bacterial pneumonia and stayed on mechanical ventilation. All of these factors can contribute toward a variable degree of immunodeficiency. Blood products including convalescent plasma can risk transmission of CMV infection, but our patient had not received convalescent plasma or other blood products during active COVID infection. The patients' serum IgG and IgM titers were both significantly high indicative of latent infection and recent activation of CMV infection. The new appearance of bilateral central and diffuse ground-glass opacities is not consistent with active COVID infection and prompted us to consider CMV pneumonia as a possibility. Colonic ileus and pneumatosis intestinalis are common features of CMV colitis but these findings can be found in colitis of other etiologies as well. Tissue biopsy and immunohistochemistry from affected organs (bronchoscopy-guided lung biopsy and colonoscopy-guided biopsy from affected portion of colon^[9]) along with the demonstration of inclusion bodies would have been the gold standard for diagnosis. However, a positive qualitative CMV DNA PCR, high IgM and IgG titers, and radiological findings of chest and abdomen helped us clinch the diagnosis.^[10]

CONCLUSION

We report the death of a previously immunocompetent patient succumbing to reactivation of CMV infection and associated end-organ dysfunction. At the same time, we

wish to draw attention to the pitfalls of prolonged use of corticosteroids and other immunomodulatory drugs which can lead to an immunodeficient state with subsequent risk of various opportunistic infections including CMV infection.

Declaration of patient consent

The authors certify that they have obtained all appropriate patient consent forms.

Financial support and sponsorship

Nil.

Conflicts of interest

There are no conflicts of interest.

REFERENCES

1. Blaize M, Mayaux J, Nabet C, Lampros A, Marcelin AG, Thellier M, *et al.* Fatal invasive aspergillosis and coronavirus disease in an immunocompetent patient. *Emerg Infect Dis* 2020;26:1636-7.
2. Chiurlo M, Mastrangelo A, Ripa M, Scarpellini P. Invasive fungal infections in patients with COVID-19: A review on pathogenesis, epidemiology, clinical features, treatment, and outcomes. *New Microbiol* 2021;44:71-83.
3. Huang I, Pranata R. Lymphopenia in severe Coronavirus disease-2019 (COVID-19): Systematic review and meta-analysis. *J Intensive Care* 2020;8:36.
4. Matthay MA, Wick KD. Corticosteroids, COVID-19 pneumonia, and acute respiratory distress syndrome. *J Clin Invest* 2020;130:6218-21.
5. Schlick K, Grundbichler M, Auberger J, Kern JM, Hell M, Hohla F, *et al.* Cytomegalovirus reactivation and its clinical impact in patients with solid tumors. *Infect Agent Cancer* 2015;10:45.
6. Tahaghoghi-Hajghorbani S, Zafari P, Masoumi E, Rajabinejad M, Jafari-Shakib R, Hasani B, *et al.* The role of dysregulated immune responses in COVID-19 pathogenesis. *Virus Res* 2020;290:198197.
7. Maillet F, Pourbaix A, Le Pluart D, Sirmay L, Postolache SA, Couvelard A, *et al.* Cytomegalovirus proctitis as a complication of COVID-19 with immunosuppressive treatments. *IDCases* 2021;24:e01111.
8. Niitsu T, Shiroshima T, Hirata H, Noda Y, Adachi Y, Enomoto T, *et al.* Cytomegalovirus infection in critically ill patients with COVID-19. *J Infect* 2021;83:496-522.
9. Yerushalmy-Feler A, Padlipsky J, Cohen S. Diagnosis and management of CMV colitis. *Curr Infect Dis Rep* 2019;21:5.
10. Ross SA, Novak Z, Pati S, Boppana SB. Overview of the diagnosis of cytomegalovirus infection. *Infect Disord Drug Targets* 2011;11:466-74.

How to cite this article: Sachan S, Singh AK, Shukla AN. Reactivation of cytomegalovirus infection in a post-COVID patient leading to cytomegalovirus pneumonia and colitis. *Indian J Med Sci* 2022;74:52-4.