

A CLINICO-EPIDEMIOLOGIC EVALUATION OF PITYRIASIS VERSICOLOR FROM A GOVERNMENT HOSPITAL, INDIA: CONVENTIONAL METHODS-STILL A THUMBS UP?

YUKTI SHARMA, SANJAY JAIN, KAPIL CHANDRA¹, K. C. MUNEGOWDA²

ABSTRACT

INTRODUCTION: *Malassezia furfur*, the etiologic agent of pityriasis versicolor (PV), is a superficially occurring, benign, chronic, and recurring fungal infection of the stratum corneum with a worldwide distribution. There is limited data from North India regarding prevalence and epidemiology. **OBJECTIVES:** The aim of this study was to give an overview of the prevalence of fungi-associated skin infections and its clinical profile, to find out the epidemiological characteristics over a period of 18 months, and to assess the use of conventional methods for diagnosis. **MATERIALS AND METHODS:** For this purpose, 300 patients suspected of having superficial mycoses, were evaluated clinically on Out Patient Department (OPD) basis in the Department of Dermatology, and diagnosis was confirmed mycologically in the Microbiology Department at Hindu Rao Hospital, Delhi. The total duration of the study period was 18 months. **RESULTS:** In the present study, 36 (12%) patients were positive for PV. The majority of the patients were young adults. There is prominent seasonal variation of the patients with a peak in August, October, and November. The most of the lesions were hypopigmented macules (83.33%) and were potassium hydroxide positive. The most commonly involved sites were trunk (80.5%), scalp (5.5%), and arm (5.5%). Seborrheic dermatitis sometimes coexisted with PV. Rare areas like groin - involvement (2.7%) were also seen. **CONCLUSION:** In conclusion, 12% of studied population was positive for tinea versicolor, which is a high prevalence for this disease. The findings of this study indicated that PV is an important health problem, and diagnosis can be easily made on OPD basis using conventional methods.

Key words: Clinico-epidemiology, pityriasis versicolor, potassium hydroxide test

INTRODUCTION

Malassezia furfur is the etiologic agent of pityriasis versicolor (PV) and it also known as tinea versicolor. It is a superficially occurring, benign, chronic, and recurring fungal infection of the stratum corneum. It has a worldwide distribution and is of common occurrence in tropical and temperate regions.^[1,2] The genus *Malassezia* is part of the normal skin microbiota, and it needs predisposing factors for multiplication and subsequent conversion from the commensal yeast form to the mycelial phase (pseudo-filamentous parasitic form).^[3] Clinically, the disease is usually asymptomatic with patients seeking medical attention for cosmetic reasons. Lesions are characterized by scaly, dyspigmented irregular macules most often occurring on the trunk and extremities, often in young adults.^[1,4,5] Cutaneous infection with *Malassezia* can manifest as white, pink, fawn, or brownish well-demarcated lesions, often coalescing, and covered with thin furfuraceous scales. The organism can readily be identified by treating skin scraping with 10% potassium hydroxide (KOH).^[6] Microscopic visualization of the fungi appears as short, thick hyphae with a large

number of variously sized spores (spaghetti and meatball appearance).^[6] This is diagnostic of PV. We have noted that superficial fungal infections are among the most common skin diseases seen in patients attending the dermatology clinic at our hospital. PV is an important public health problem because of the increase in immunosuppressive states. Large-scale studies in India are scarce, and so the baseline incidence/prevalence of tinea versicolor is not firmly established. The aim of this study was to give an overview of the prevalence of fungi-associated skin infections and its clinical profile, to find out the epidemiological characteristics over a period of 18 months, and to assess the use of conventional methods.

MATERIALS AND METHODS

In the present study, 300 patients suspected of having superficial mycoses, attending to the Dermatology Out Patient Department (OPD) at Hindu Rao Hospital, Delhi, over a period of 18 months (January 2010-June 2011), were sampled. The skin scraping method was used for sampling from the infected skin of patients. Microscopic examination of the samples was performed following treatment with an aqueous solution of 10% KOH. The presence of short and curved pseudohyphae with clusters of yeasts and budding cells confirmed the disease.

A detailed clinical history with particular emphasis on patient's age, sex, socioeconomic status (modified

Departments of Microbiology and ¹Dermatology, Hindu Rao Hospital, New Delhi, ²Department of Microbiology, Mandya Institute of Medical Sciences, District Hospital, Mandya, Karnataka, India

Address for correspondence:

Dr. Yukti Sharma, 272 Sfs (Dda) Flats, Mukherjee Nagar, New Delhi, India.
E-mail: dryukti2006@yahoo.com

Kuppuswamy scale), symptoms, and climatic influence was taken. Inquiry was made for the use of cosmetics, talcum powder, shampoo, oil, synthetic clothing, and condition of the personal hygiene. A thorough clinical examination was done to determine the color, characteristics and distribution of lesions of the patients, and any other associated dermatological or systemic diseases.

RESULTS

In the present study, 36 (12%) patients were positive for PV. These included 28 (77.77%) males and 8 (22.2%) females with a male/female ratio of 3.5:1. The age of patients was ranged from 6 to 56 years. The most of the patients were young adults. The highest prevalence of tinea versicolor was seen in patients within age group 21-30 years (38.88%) [Figure 1].

The prominent locations of lesion on the patient's body were as follows: Trunk (80.5%), scalp (5.5%), and arm (5.5%) [Figure 2].

The results also show that the common months of manifestation were August, October, and November [Figure 3].

Morphologically, most lesions were hypopigmented macules in 30 patients (83.33%) [Figure 4]. No other associated

dermatological or systemic illness was seen. Coexistent seborrheic dermatitis was observed in 2 (5.5%) patients. 50% patients were from upper lower and lower socioeconomic status. No definite association was found with the use of soap, shampoo, oil, synthetic clothing, talcum powder, and cosmetics.

DISCUSSION

PV, a disease with a worldwide distribution,^[7,8] is diagnosed based on clinical findings and confirmed by direct microscopy [Figure 5].^[7] The present study revealed a mycological positivity of 36 (12%) out of 300 patients by direct microscopy. Culture was not done since *Malassezia* species is a constituent of normal skin flora and its isolation using a lipid-rich medium (e.g., olive oil over malt extract or a Tween medium) is of no diagnostic value and is not routinely recommended.^[9] Sivakumar *et al.* reported 17.58% cases of PV (16 cases of PV out of total 91 cases)^[10] which is comparable to the results of the present study, whereas that reported by a study from Iran^[11] was 30.6% which is well above in comparison to the present findings.

Male preponderance, seen here, has also been reported by Ghosh *et al.*^[9] and Zarei-Mahmoudabadi *et al.*^[11] In contrast, some studies reported that both sexes are equally prone to develop PV.^[12]

Age group 21-30 years was found to be the most commonly affected. These data are in agreement with studies in

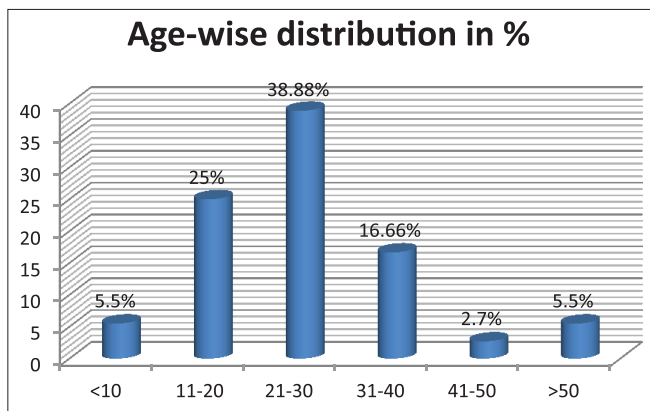


Figure 1: Distribution of pityriasis versicolor patients according to the age group

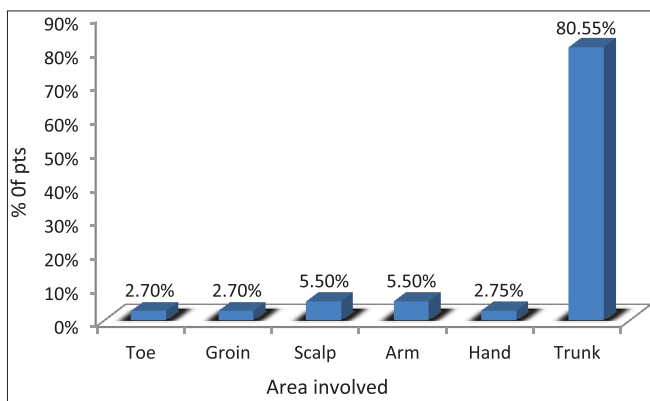


Figure 2: Distribution of pityriasis versicolor patients according to the site of lesions

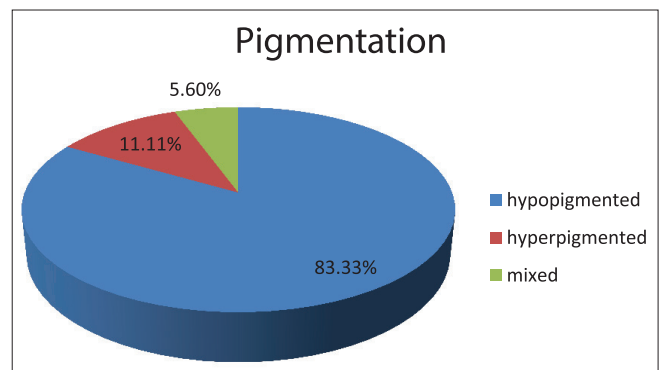


Figure 3: Distribution of pityriasis versicolor patients according to the color of lesions

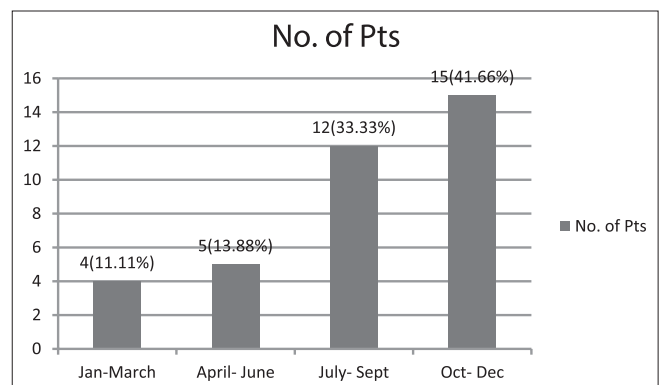


Figure 4: Distribution of patients according to month of presentation

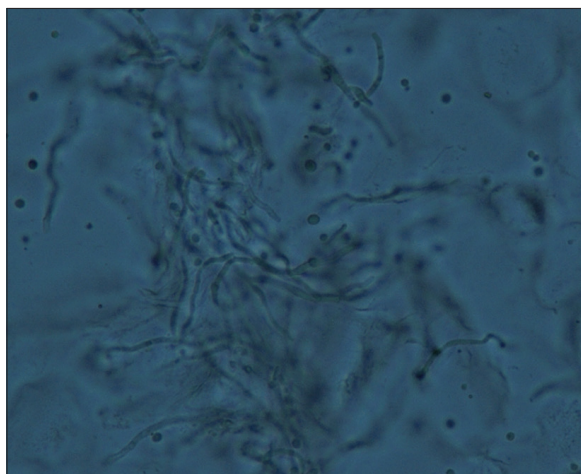


Figure 5: Photomicrograph of pityriasis versicolor - "spaghetti and meatball appearance" seen in potassium hydroxide mount

the literature that emphasize the higher frequency of this infection in young people due to the lipophilic characteristics of this type of fungus.^[7,11] This may be due to hormonal changes and increase in sebaceous gland activity. This is in consensus with findings by Rao *et al.* (age group 21-30 years).^[12]

The most common affected areas were trunk (80.5%), scalp (5.5%), and arm (5.5%), whereas Zarei-Mahmoudabadi *et al.*^[11] reported the most affected areas were neck (34.6%) followed by trunk (17%) and chest (16.3%). Higher incidences on the chest, back, and face have been reported elsewhere.^[11,12] Distribution of lesions usually parallels the density of sebaceous secretion distribution. We also observed lesions in unusual locations such as groin. Probably, the high ambient temperature and humidity of this region encourage PV spread.

The seasonal trend showed that the most common months of manifestation were August, October, and November [Figure 3]. Almost similar observation was done by Ghosh *et al.* (August and September (26.36%).^[9] Some studies have also revealed clustering of cases (35%) during the summer months.^[9]

Hypopigmented macules were seen in 30 patients (83.33%) followed by either mixed hypo- and hyper-pigmented (5.6%) or only hyperpigmented (11.11%) [Figure 3]. These findings are comparable with Ghosh *et al.* (hypopigmented lesions; 81.83%)^[9] and Rao *et al.* (hypopigmented lesions; 75%).^[12] However, Zarei-Mahmoudabadi *et al.* found 50% of the cases had hyperpigmentation followed by hypopigmentation (36.2%) and erythematous lesions (13.8%),^[11] which stands well in contrast to the present study.

Around 2 patients (5.5%) showed coexistent seborrheic dermatitis, whereas 10% coexistence was seen by Ghosh *et al.*^[9]

About 50% patients were from upper lower and lower socioeconomic status. Delhi is located in tropical region

with hot and humid conditions from April to September. Several reports showed that hot and humid conditions, lower socioeconomic status, and hygiene are susceptible factors for presenting PV.^[13,14] Rao *et al.* and^[12] Bélec *et al.*^[15] believe that good or poor hygiene of the clothing had no significant influence on the prevalence of PV. The present study, however, showed no such relation.

In the present study, no definite association was found with the use of soap, shampoo, oil, synthetic clothing, talcum powder, and cosmetics. This is in contrast to the studies from Kerala who found less prevalence of tinea capitis since people regularly applied coconut oil or other types of oil on their hair.^[10,16]

The two conventional methods for fungi identification are direct microscopy (KOH) and fungal culture. The microscopic method is more sensitive for showing the presence of fungi, but the isolation of a specific genus and species identification of the pathogen requires fungal culture, which is often not very fruitful. Although culture is considered to be more sensitive than direct microscopy in mycological isolations, the present study focuses on the conventional method of diagnosing PV. Direct microscopy in PV lesions shows the characteristic "banana and grapes" or "spaghetti and meatball" appearance which can be easily differentiated from candidal lesions (hyphae or pseudohyphae with blastoconidiating cells). Some studies suggest that the clinical features of PV are typical, and skin scrapings for a laboratory diagnosis are unnecessary,^[17] but we found KOH microscopy to be a simple, economical test which is easy to perform and can also be done in the OPD. It requires minimum infrastructure and technical expertise to perform this test. In a developing country like ours, where culture of fastidious organisms-like *Malassezia* with special media and molecular study may not be possible in most setups, diagnosis with direct KOH microscopy might be an easy and cheap alternative. However, sensitivity of this diagnostic test depends on the method of the sampling, preparation of sample, failure rate of microscopy and culture, and the final interpretation of results.

Culturing *Malassezia* may be cumbersome since it requires special media (Sabouraud agar and Dixon's medium were used, with the addition of olive oil in both cases) with prolonged incubation. A study from Brazil reported almost equal result whereby positive result by direct examination was 77% and that by fungal culture was 75%.^[18] Almost similar findings were seen with a study from Kerala (out of 16 suspected cases of PV, 9 positive with direct microscopy).^[10]

Data regarding PV are scarce from North India. This study helps to outline the prevalence and epidemiological aspects of PV apart from emphasizing on the use of conventional methods to aid in diagnosis.

CONCLUSION

The findings of this research indicated that PV is an important public health problem, and diagnosis can be easily made on OPD basis using conventional methods. We emphasize the use of conventional methods for diagnosing PV, rather than treating empirically on the basis of clinical findings. Further, new systemic and topical antifungal therapies make the study of epidemiology and the extent of impact of this infection more important. In general, people should be more aware and physicians should be more clinically alert thereby initiating prompt investigation and treatment.

REFERENCES

- Gupta AK, Batra R, Bluhm R, Boekhout T, Dawson TL Jr. Skin diseases associated with *Malassezia* species. *J Am Acad Dermatol* 2004;51:785-98.
- Gupta AK, Kohli Y, Faergemann J, Summerbell RC. Epidemiology of *Malassezia* yeasts associated with pityriasis versicolor in Ontario, Canada. *Med Mycol* 2001;39:199-206.
- Klenk AS, Martin AG, Heffernan MP. Yeast infections: Candidiasis, pityriasis (tinea) versicolor. In: Freedberg IM, Eisen AZ, Wolf K, Austen KF, Goldsmith LA, Katz SI, editors. *Fitzpatrick's Dermatology in General Medicine*. 6th ed. New York: McGraw-Hill; 2003. p. 2006-18.
- Crespo Erchiga V, Delgado Florencio V. *Malassezia* species in skin diseases. *Curr Opin Infect Dis* 2002;15:133-42.
- Ashbee HR, Evans EG. Immunology of diseases associated with *Malassezia* species. *Clin Microbiol Rev* 2002;15:21-57.
- Gupta AK, Batra R, Bluhm R, Faergemann J. Pityriasis versicolor. *Dermatol Clin* 2003;21:413-29, v-vi.
- Borelli D, Jacobs PH, Nall L. Tinea versicolor: Epidemiologic, clinical, and therapeutic aspects. *J Am Acad Dermatol* 1991;25:300-5.
- Mackie TJ, Collee JG, McCartney JE. Mackie & McCartney *Practical Medical Microbiology*. 14th ed. New York: Churchill Livingstone; 1996.
- Ghosh SK, Dey SK, Saha I, Barbhuiya JN, Ghosh A, Roy AK. Pityriasis versicolor: A clinicomycological and epidemiological study from a tertiary care hospital. *Indian J Dermatol* 2008;53:182-5.
- Sivakumar N, Karthikeyan A, Vivek A, Santhamani MD. Prevalence of etiological agents in superficial mycoses with reference to dermatophytoses and pityriasis versicolor. *Internet J Microbiol* 2009;7: 13-18.
- Zarei-Mahmoudabadi A, Zarrin M, Mehdinezhad F. Seborrheic dermatitis due to *Malassezia* species in Ahvaz, Iran. *Iran J Microbiol* 2013;5:268-71.
- Rao GS, Kuruvilla M, Kumar P, Vinod V. Clinico-epidemiological studies on tinea versicolor. *Indian J Dermatol Venereol Leprol* 2002;68:208-9.
- He SM, Du WD, Yang S, Zhou SM, Li W, Wang J, *et al*. The genetic epidemiology of tinea versicolor in China. *Mycoses* 2008;51:55-62.
- Asadi MA, Droudgar A, Houshyar H. Prevalence of cutaneous mycoses among sanitary workers of city municipality of Kashan, 1998. *Feyz, Kashan Uni Med Sci Health Serv* 1998;9:92-9.
- Bélec L, Testa J, Bouree P. Pityriasis versicolor in the central African republic: A randomized study of 144 cases. *J Med Vet Mycol* 1991;29:323-9.
- Hajini GH, Kandhari KC, Mohapatra LN, Bhutani LK. Effect of hair oils and fatty acids on the growth of dermatophytes and their *in vitro* penetration of human scalp hair. *Sabouraudia* 1970;8:174-6.
- Available from: <http://www.file:///C:/Mycology Online/Malassezia infections.htm>.
- Petry V, Tanhausen F, Weiss L, Milan T, Mezzari A, Weber MB. Identification of *Malassezia* yeast species isolated from patients with pityriasis versicolor. *An Bras Dermatol* 2011;86:803-6.

How to cite this article: Sharma Y, Jain S, Chandra K, Munegowda KC. A Clinico-epidemiologic evaluation of pityriasis versicolor from a government Hospital, India: Conventional methods-still a thumbs up?. *Indian J Med Sci* 2016;68:63-66.

Source of Support: Nil. **Conflict of Interest:** None declared.

Copyright: © the author(s), publisher and licensee Medip Academy. This is an open access article distributed under the terms of the Creative Commons Attribution-NonCommercial-ShareAlike 3.0 License, which permits unrestricted noncommercial use, distribution, and reproduction in any medium, provided the original work is properly cited.